Jurnal Medical Aradean (Arad Medical Journal)
Vol. XVI, issue 1-4, 2013, pp. 100-105

Implants- immediate restoration of postextraction edentation both esthetically and functionally

Otilia Stana (Gag), Lileloana Elena, Freiman Paul, Mugur Popescu, Elisei Gabriela, Sebesan Voicu, Vincze Daniela, Alina Marian, Stana Ademir Horia

"VasileGoldis" Western University of Arad, Faculty of Medicine, Department of Dentistry

ABSTRACT
Immediate implants are a great choice for people who need immediate restoration of dental arcades both functionally but also esthetically. Immediate implants offer to the patient a psychological comfort, but also reduces the costs, which makes them more attractive to the them. Our study was made in a dental clinic, and involved a number of 10 patients. After assessing the case and determining the treatment plan for each patient was established that the implants will be inserted immediately after extraction. Oral rehabilitation of the edentation was made by fixed suprastructures connected to the implants. Patients were recalled at 3, 6 and 12 months later and the implants were examined both clinical and radiographic. The success rate was over 95% indicates that immediate implants inserted after extraction and loaded immediately after insertion for restoration of masticatory function and esthetics, are a very good option for the total edentulous patient..

Keyword: implants, immediate implants, late loading implants, prosthetic restoration, esthetic.

INTRODUCTION
For achieving a continuity of the dental arches postextractionally, immediate implants are a great solution. They assure in the first place a psychological comfort for the patient but also anatom
Initial implant stability, implant surface characteristics, bone quality, bone healing, intern prosthesis design, and occlusion pattern during the healing phase have been identified as influential factors in successfully achieving osseointegration with modified loading protocols.(Chiapasco M et all)
The use of osseointegrated dental implants has made it possible to rehabilitate edentulous jaws to near-normal levels of esthetics and function. The predictability of dental implants ad modum Brånemark has been shown to be high when following a two-stage surgical procedure with a submerged healing period of 3 months in the mandible and of 6 months in the maxilla.(Adell R et all, Henry PJ et all, Lekholm U et all)
The need for immediate implants and immediate restauration is higher for the anterior region of the dental arch, because it implies the patients esthetic needs, that are a very important for them because it makes them more comfortable with themselves and more important that they can socialize easy. Maló and colleagues reported on a concept of immediate implant function in the esthetic zone in a retrospective clinical study from one clinic, giving a 95.7% survival rate.
Also there is a need for immediate implants and immediate restauration in the posterior region of dental arch where mastication function is the most important. When it is restored the patients benefit not only from the immediate restauration of the mastication function but also they are protected from any general disease that are induced by a low quality of the mastication process involving headaches, stomach pain up to the possibility for diseases of the digestive system etc.
Immediate implant function provides an evident psychological benefit for the patient as well as a potential cost reduction and, therefore, increases the attractiveness of implant treatment. This study addresses its potential in the esthetic regions, where published clinical documentation currently is limited to one pilot study of 14 patients with single-tooth losses in the region anterior to the molars.(Ericsson I et all)
The advantages of immediate implant placement have been reported to include reductions in the number of surgical interventions and in the treatment time required.(Lazzara RM., Parel SM et all). It has also been suggested that ideal orientation of the implant, (Schultz AJ., Werbitt MJ et all), preservation of the bone at the extraction site, (Parel SM et all, Schultz AJ., Werbitt MJ et all)and optimal soft tissue esthetics (Werbitt MJ et all) may be achieved.
The objective of this study is to determine which implant, with immediate loading or later loading has the most benefits for the patients but also which one is more correct from the scientifically and clinically point of view.

MATERIALS AND METHODS
For our study we selected 10 patients, that were in concordance with the requirements of inserting dental implants. They did not had any heavy smoking habit, thyroid disease, uncontrolled diabetes, neurologic diseases previously they had local radiotheraphy, or undergoing chemotherapy, medication (bisphosphonates) for osteoporosis, no periodontal

disease. They all had a healthy gingival structure, a good oral hygiene, consisting of a thorough brushing together with the use of adjunctive brushing means.
For every patient we have made a thorough clinical control and we asked for laboratory tests such as radiography (OPG), computed tomography (3D CT-CBCT), and blood tests.
After we assessed all patients from the clinically point of view and we examined all complementary test, we found that all of them were in accordance with the requirements of inserting implants.

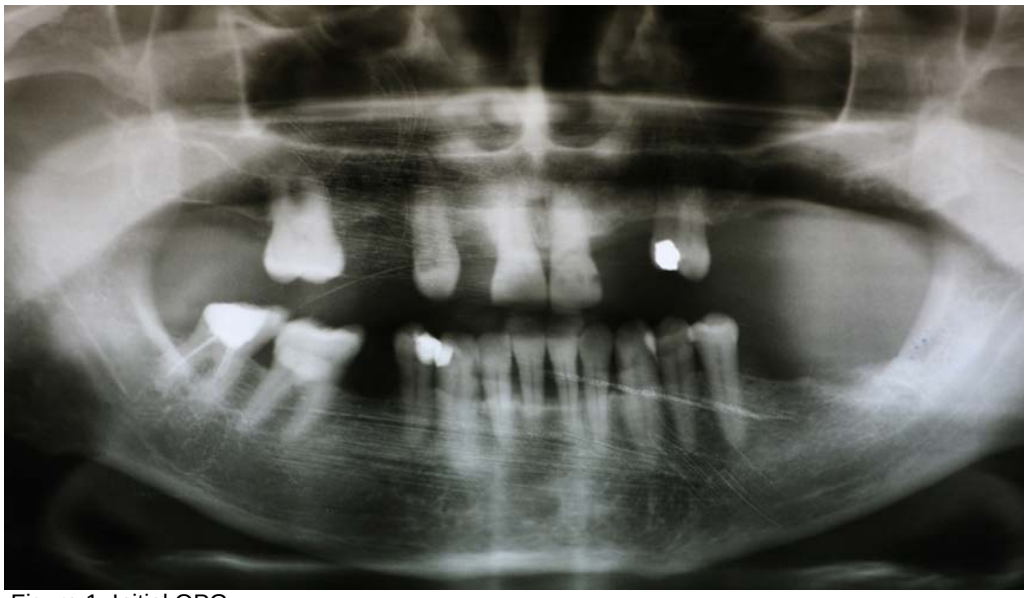

Figure 1. Initial OPG

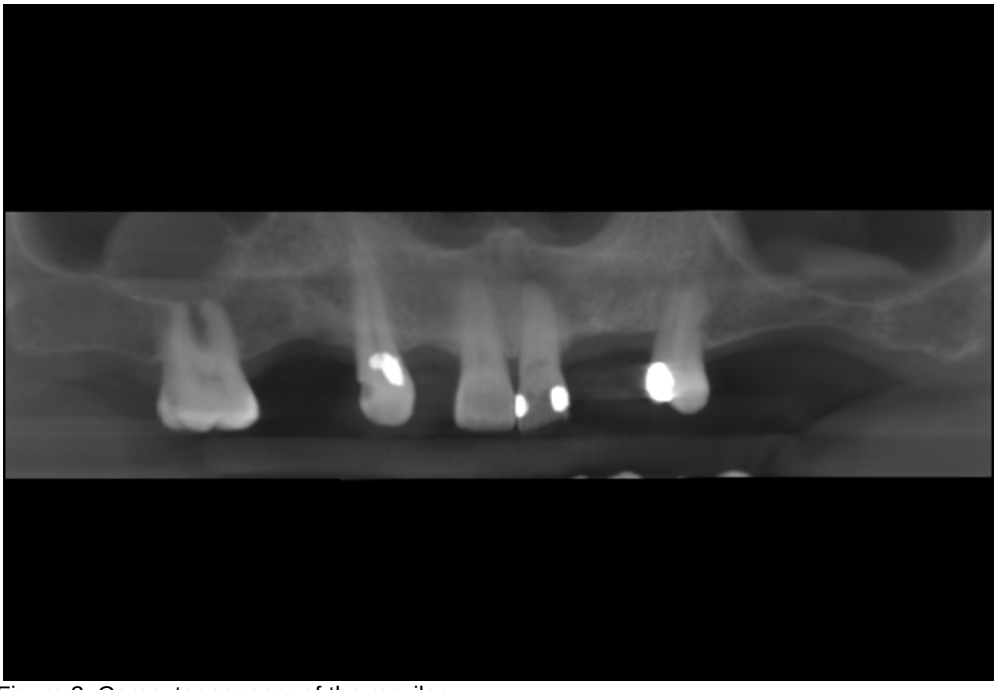

Figure 2. Computer scanner of the maxilar

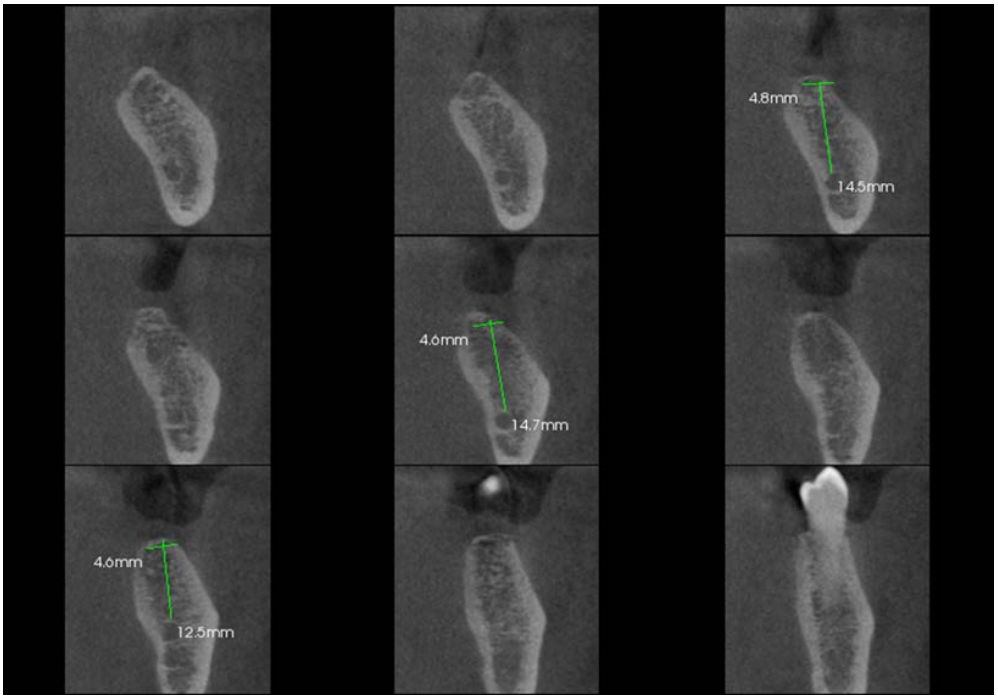

Figure 3. Volumetric 3D CT-CBCT

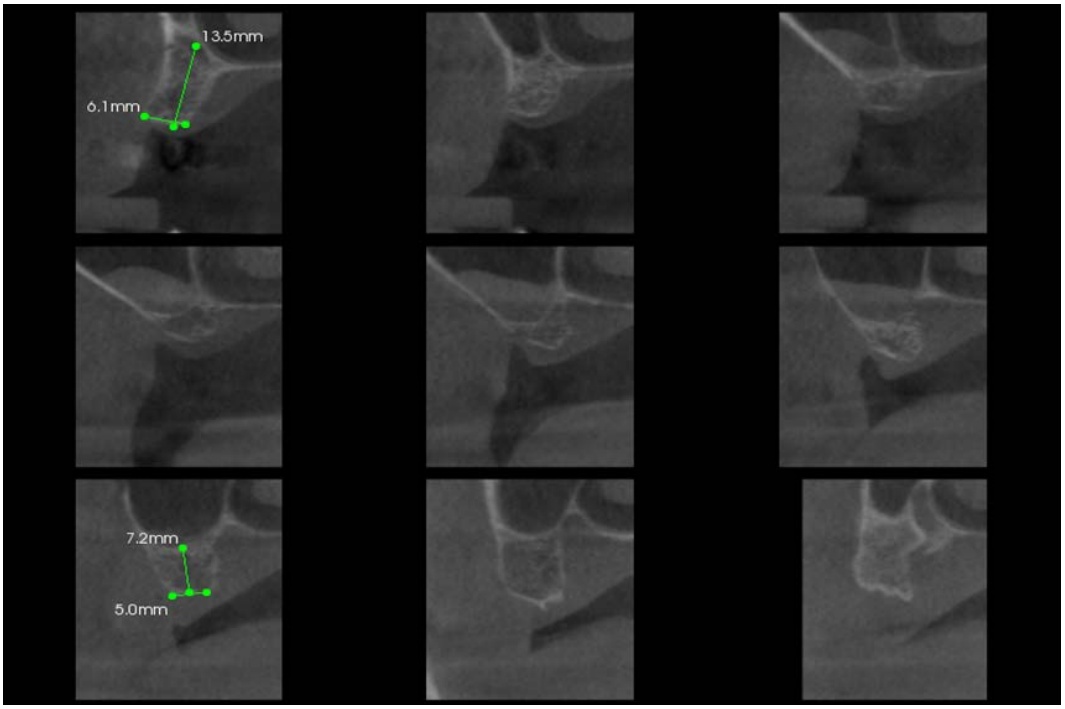

Figure 4. Different sections on volumetric 3D CT-CBCT

From the 10 selected patients we inserted implants with immediate loading at 6 of them, and at 4 patients we had placed late loading implants.
The procedure for late loading implants was as follow: in the treatment of the case we went through the following steps: preoperative medication. In the surgical terms we had made: loco-regional anesthesia and we had follow the stages of endosseous implants insertions. The last one was made thorough: the mucoperiosteal incision and elevated it, implants insertion at 1.4 - 1.5, mounting screw cover and suture wound .

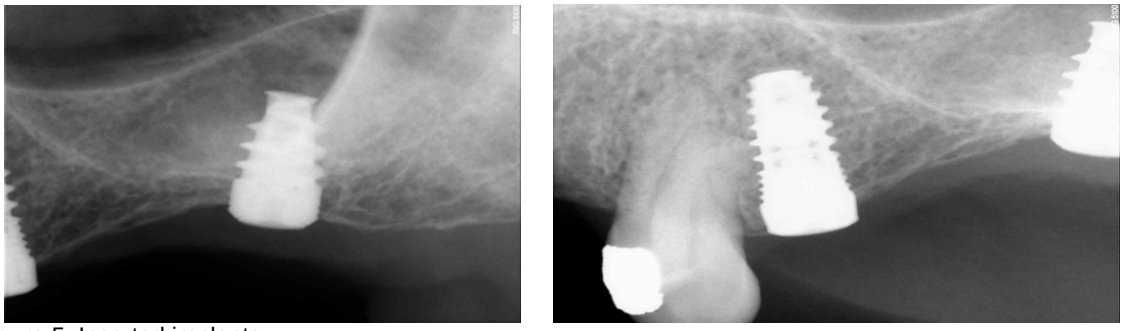

Figure 5. Inserted implants

We had conducted post-operative: the analgesics, anti-inflammatory terapy, antibiotics, endooral lavage, Dexamethasone. After six months from the inserting of implants we had: discovered the implants using electrocautery or circular knives, we had mounted the healing screw.

After 3 weeks of healing: we had made the impression of the prosthetic field and after it was finished we placed the final prosthetic.



Figure 6. The impression

Figure 7. The final prosthetic

Figure 8. Initial case and the extraction of the compromised tooth

When we placed the immediate implants we had followed the same steps but the impression was made in the same day with the placing of implants insertion and the temporary prosthetic were placed after 70 hours. When the final prosthetic was made and finished we placed it in the oral cavity after 3-4 months.

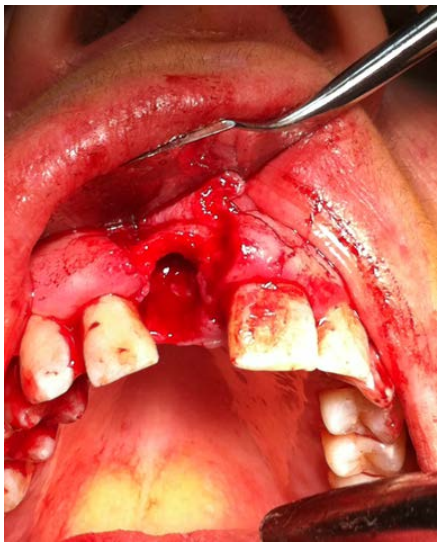

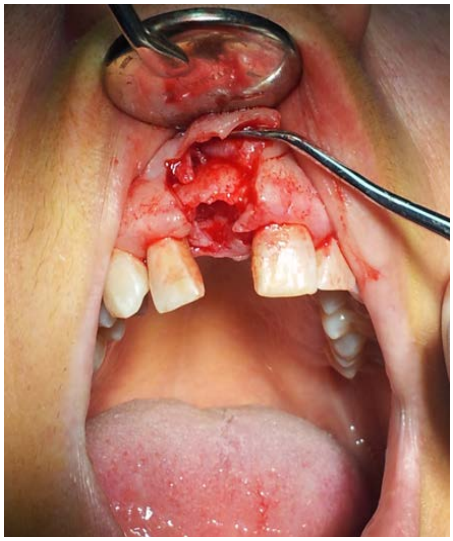

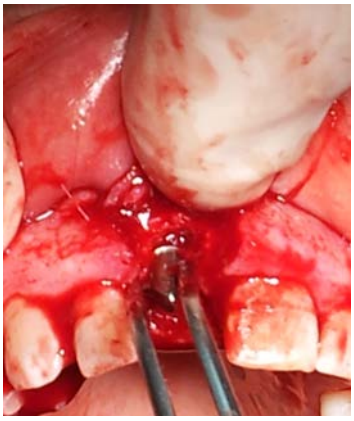

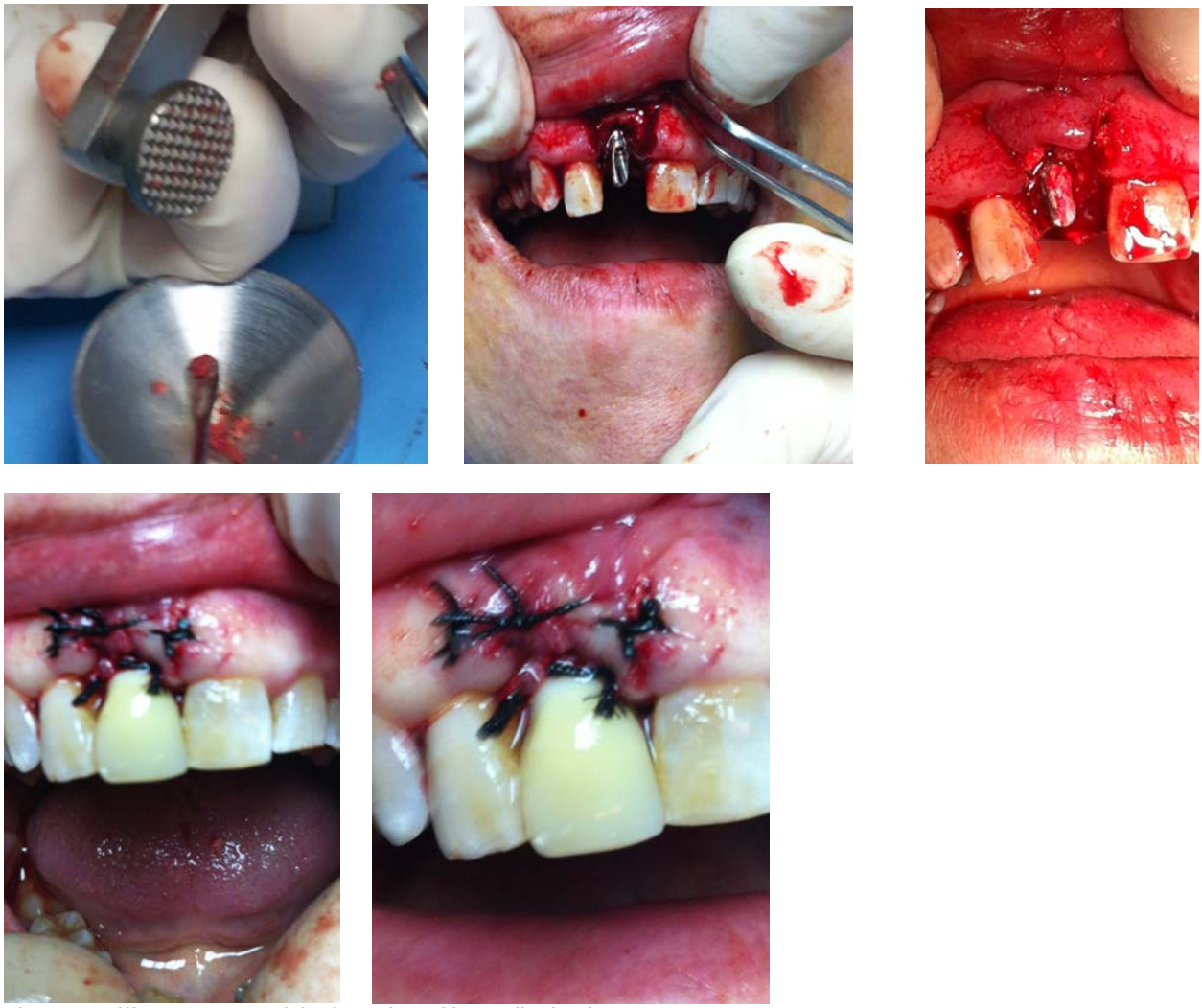

Figure 9. Different stages of the insertion of immediat implant

RESULTS AND DISCUSSION

In the first stage of placing the implants there is no difference in inserting the implants but the main distinction is that at the end of the procedure for the immediate implants the temporary prosthesis is placed immediately after the insertion of implants.

In our study we examined the patients every 6 months for 1 ½ years. When we evaluated them we considered the following: if the implants are still on the dental arch, if the inflammation symptoms are present, if there is gum or bone retraction. All of the above were examined at both type of implants, and in the end we compared the results.

After 6 months, when we recall the patients and we examined them we observed that all the implants were on the dental arch, there were no inflammatory symptoms, but there was a small retraction at the bone, which was between 0,3 at the late loading implants and it was 0,5 at the immediate loading implants. This is considered a normal retraction in the specialized literature.

After 12 months at the examining the 16 patients we observed that all implants were in the oral cavity, there were no gum inflammation, and the bone retraction was 0,5mm at the late loading implants and of 0,7mm at the immediate loading implants.

After 18 months all inserted implants were on the dental arch, there was no inflammation and the bone retraction was at the same level as at 12 months. This means that the dental implants were successfully integrated.

CONCLUSIONS

Immediate implants have much more benefits than the late implants, for the patients because it restores immediate the aesthetic function as well as masticatory and phonetic functions, so it creates a beneficial psychological comfort for the patient.

Because immediate implants have a more pronounced bone retraction than the late loading implants it shows us that those with late loading have a better osseointegration, and suggests that the rate of success, of prosthetic restorations on immediate loading implants, is influenced by it.

REFERENCES

Adell R, Eriksson B, Lekholm U, Brånemark PI, Jemt T. A long-term follow-up study of osseointegrated implants in treatment of totally edentulous jaws. Int J Oral Maxillofac Implants 1990; 5:347–359.
Chiapasco M. Early and immediate restoration and loading of implants in completely edentulous patients. Int J Oral Maxillofac Implants 2004;19(suppl):76–91.
Ericsson I, Nilsson H, Lindh T, Nilner K, Randow K. Immediate functional loading of Brånemark single-tooth implants. Clin Oral Impl Res 2000; 11:26–33.
Henry PJ, Laney WR, Jemt T, et al. Osseointegrated implants for single-tooth replacement. A prospective 5-year multicenter study. Int J Oral Maxillofac Implants 1996; 11:450–455.
Lazzara RM. Immediate implant placement into extraction sites: Surgical and restorative advantages. Int J Periodontics Restorative Dent 1989;9:333–343.
Lekholm U, Gunne J, Henry P, Higuchi K, Lindén U, Bergström C. Survival of the Brånemark implant in partially edentulous jaws. A 10-year prospective multicenter study. Int J Oral Maxillofac Implants 1999; 14:639–645.
Maló P, Rangert B, Dvärsäter L. Immediate function of Brånemark implants in the esthetic zone: a retrospective clinical study with 6 months to 4 years follow-up. Clin Implant Dent Relat Res 2000; 2:138–146.
Parel SM, Triplett RG. Immediate fixture placement: A treatment planning alternative. Int J Oral Maxillofac Implants 1990;54:337–345.
Schultz AJ. Guided tissue regeneration (GTR) of nonsubmerged implants in immediate extraction sites. Pract Periodontics Aesthet Dent 1993;52:59–65.
Werbitt MJ, Goldberg PV. The immediate implant: Bone preservation and bone regeneration. Int J Periodontics Restorative Dent 1992;12:207–217.